

# Prolonged survival after hepatic artery embolization in patients with midgut carcinoid syndrome

C. Swärd<sup>1,2</sup>, V. Johanson<sup>1,2</sup>, E. Nieveen van Dijkum<sup>1,2</sup>, S. Jansson<sup>1,2</sup>, O. Nilsson<sup>1,3</sup>, B. Wängberg<sup>1,2</sup>, H. Ahlman<sup>1,2</sup> and L. Kölby<sup>1,2</sup>

<sup>1</sup>Lundberg Laboratory for Cancer Research and Departments of <sup>2</sup>Surgery and <sup>3</sup>Pathology, Sahlgrenska University Hospital, Göteborg, Sweden

Correspondence to: Dr L. Kölby, Institute for Clinical Sciences, Department of Surgery, Sahlgrenska University Hospital, Göteborg University, SE-413 45 Göteborg, Sweden (e-mail: lars.kolby@surgery.gu.se)

**Background:** Hepatic artery embolization (HAE) is a palliative treatment for patients with liver metastases from neuroendocrine tumours. HAE reduces hormonal symptoms, but its impact on survival has been questioned.

**Methods:** Biochemical responses and survival in consecutive patients with disseminated liver metastases from midgut carcinoid tumours were studied after HAE. Repeat HAE was performed in selected patients with radiological and biochemical signs of progression.

**Results:** Of 107 patients who had HAE, the median survival from the first procedure was 56 (range 1–204) months. Prolonged survival showed a strong correlation with reduction of urinary 5-hydroxyindoleacetic acid ( $P = 0.003$ ) and plasma chromogranin A ( $P = 0.001$ ) levels. The biochemical response to repeat HAE was similar to that for the first procedure ( $P = 0.002$ ). The complication rate was low (7.5 per cent), as was the mortality rate (1.9 per cent) within 1 month of HAE.

**Conclusion:** HAE is safe, provides good control of hormonal symptoms, and prolongs survival in biochemically responsive patients. It is a valuable palliative option for patients with midgut carcinoid syndrome due to liver metastases and can be repeated in patients with a favourable response to the first procedure.

Paper accepted 13 January 2009

Published online in Wiley InterScience (www.bjs.co.uk). DOI: 10.1002/bjs.6587

## Introduction

Hepatic artery embolization (HAE) is a vascular intervention for the treatment of patients with liver metastases from neuroendocrine tumours. Embolization causes relatively selective ischaemia in the metastases, as their main blood supply is from the hepatic artery whereas the remaining liver parenchyma is supplied from the portal vein<sup>1</sup>. Interventions involving the hepatic artery for therapeutic purposes were first proposed in 1952<sup>2</sup> and various techniques to achieve tumour ischaemia were subsequently employed. Ligation of the hepatic artery, however, rarely achieved adequate ischaemia owing to its rich collateral blood supply. The technique was associated with a high mortality rate, and repeat interventions were not possible<sup>3</sup>.

The current method of choice is selective HAE, in which the hepatic artery is first catheterized followed by the injection of embolization material to induce temporary ischaemia<sup>4</sup>. HAE can be performed safely in most patients, but contraindications include tumour burden exceeding 50 per cent of the liver volume, portal vein occlusion, hyperbilirubinaemia and persistently raised liver enzyme levels<sup>5</sup>. Embolization is often accompanied by adverse reactions such as pain, fever, nausea and a transient increase in liver enzymes, and necessitates a hospital stay of a few days. Severe complications may include gallbladder ischaemia, pancreatitis, liver abscess, vascular damage, hormonal crisis and the hepatorenal syndrome. The mortality rate at centres with wide experience of the procedure is less than 5 per cent<sup>5,6</sup>.

HAE is a well established treatment for the control of hormonal symptoms<sup>6–11</sup>. In a study of 64 consecutive patients with the midgut carcinoid syndrome and

The Editors are satisfied that all authors have contributed significantly to this publication

disseminated liver metastases, HAE was effective in reducing hormone levels and symptoms in those with clear tumour regression; the biochemical effect lasted for several years<sup>11</sup>.

Patients with resectable liver lesions are best treated by curative liver surgery<sup>11</sup>. A survival advantage for HAE has been shown in small series<sup>12,13</sup>, but the impact on overall survival still needs to be confirmed. The aim of the present study was to evaluate the biochemical response and overall survival after HAE in a large series of consecutive patients with multiple liver metastases from midgut carcinoid tumours.

## Methods

Between 1987 and 2006, HAE was used to treat 107 consecutive patients (54 women and 53 men) with midgut carcinoid syndrome and irresectable liver metastases. Data were analysed retrospectively to determine biochemical response (hormone markers and liver enzymes) and survival.

Patients with irresectable liver metastases and hormonal symptoms associated with a urinary 5-hydroxyindoleacetic acid (5-HIAA) level that had increased at least twofold or radiological progression of liver metastases were considered for the procedure. Contraindications to HAE were tumour burden exceeding 50 per cent of the liver volume, portal vein occlusion and hyperbilirubinaemia. Relative contraindications were contrast allergy, coagulopathy, persistently raised liver enzymes, extrahepatic tumour dominance and poor general performance status.

## Embolization procedure

HAE was performed by means of a transfemoral approach by experienced interventional radiologists using a Tracker<sup>®</sup>-18 infusion catheter (Target Therapeutics, Los Angeles, California, USA)<sup>14,15</sup>. Patency of the portal vein was confirmed by angiography. One hepatic artery was embolized in each session. In patients with a large tumour burden, superselective embolization of a smaller segment was performed<sup>10</sup>. The embolization material used was initially absorbable gelatine powder and, later in the series, polyvinylalcohol particles (45–150 µm). Patients were given epidural anaesthesia and were closely monitored haemodynamically. Broad-spectrum antibiotics and somatostatin analogues were used during the procedure.

The number of procedures required for complete treatment of the liver metastases was related to the vascular anatomy and tumour location. Before the procedure,

levels of the hormonal tumour markers urinary 5-HIAA and plasma chromogranin A (CgA) were determined and computed tomography (CT) of the abdomen was performed. These investigations were repeated 3 months after the completion of treatment. Survival was estimated from the first HAE procedure (from the onset of liver-targeted therapy), not from the time of diagnosis.

## Repeat hepatic artery embolization

Repeat HAE was considered when progressive disease was detected by two consecutive CT scans with an interval of at least 6 months, together with a urinary 5-HIAA concentration increased at least twofold relative to that recorded after the previous HAE treatment. Repeat HAE was performed in 19 of the 107 patients at a mean(s.e.m.) of 47(5) months after the first procedure.

## Statistical analysis

Stepwise Cox regression analysis was used to build a statistical model to select variables that correlated with survival; factors included were sex, age, previous octreotide treatment, previous treatment with cytotoxic agents, previous interferon treatment, presence of metastases to regional lymph nodes, peritoneum or skeleton, increased liver aminotransferase levels in response to HAE (within 3 days), and changes in urinary 5-HIAA or plasma CgA levels at follow-up. Cox regression was used to study the relationship between survival and the percentage change in urinary 5-HIAA and plasma CgA levels, and also to determine the influence on survival of liver aminotransferase levels after HAE<sup>16</sup>. Pearson's correlation coefficients were calculated to study the co-variation between biochemical responses following the first and repeat HAE procedures.  $P < 0.050$  was considered statistically significant.

## Results

A total of 107 patients underwent 213 procedures. Each patient had HAE between one and four times, 4–6 weeks apart. The mean(s.e.m.) age of patients was 64(0.9) (range 32–81) years at diagnosis and 66(0.9) (range 33–81) years at the first HAE. The mean(s.e.m.) urinary 5-HIAA level before the first HAE was 400(51) (reference value less than 50) µmol 24 h. Ninety-three patients (86.9 per cent) had normal liver enzyme levels at entry.

All but one patient had undergone resection of the primary tumour, excision of regional lymph nodes and prophylactic cholecystectomy before the HAE procedure.

In five patients, a limited liver resection with non-curative intent had been performed. Nine patients had received interferon and two had received cytotoxic treatment with no objective response before HAE.

The mean(s.e.m.) time from diagnosis to the first HAE procedure was 28(5) months. Nineteen patients had repeat HAE because of progression. Fifty-four patients had a complete record for urinary 5-HIAA levels before the onset of treatment and at follow-up 1–6 months after the completion procedure; 37 had a complete record for plasma CgA.

Two patients died within 1 month of HAE, one from hepatorenal syndrome and the other from rapidly progressive disease, giving a mortality rate of 1.9 per cent. One patient with HAE-related sepsis had an uneventful outcome. Minor complications included liver abscess (four patients), mild pancreatitis (one) and accidental occlusions of the common hepatic artery (two), resulting in a complication rate of 7.5 per cent.

### Biochemical and symptomatic response

Twenty-six of 54 patients had a greater than 50 per cent decrease in urinary 5-HIAA levels, and 19 of 37 had a greater than 50 per cent decrease in plasma CgA concentration. The mean(s.e.m.) decrease in urinary 5-HIAA was 30.4(8.0) per cent, and that for plasma CgA was 28.0(10.4) per cent.

Seventy-six patients (71.0 per cent) experienced symptomatic relief, including less diarrhoea, reduced flushing or improved general well-being reflected by weight gain.

### Survival

Median survival from the first HAE procedure for the whole series was 56 (range 1–204; 95 per cent confidence interval (c.i.) 45 to 67) months (Fig. 1). Multivariable stepwise Cox regression showed that male sex (hazard ratio (HR) 5.80 (95 per cent c.i. 1.05 to 32.02);  $P = 0.044$ ), percentage change in urinary 5-HIAA (HR 0.97 (0.95 to 0.99);  $P = 0.005$ ), percentage change in plasma CgA (HR 0.97 (0.96 to 0.99);  $P = 0.003$ ) and postembolization aspartate aminotransferase (AST) levels (HR 1.10 (1.04 to 1.17);  $P = 0.003$ ) were independent predictors of survival. There was a strong correlation according to Cox regression between increased survival and reduced urinary 5-HIAA levels (HR 0.99 (95 per cent c.i. 0.99 to 1.00);  $P = 0.003$ ) or reduced plasma CgA concentration (HR 0.99 (0.98 to 1.00);  $P = 0.001$ ). There was a 6-month gain in estimated survival when the reduction in urinary 5-HIAA was 50 per cent or greater *versus* no reduction in urinary 5-HIAA, and a

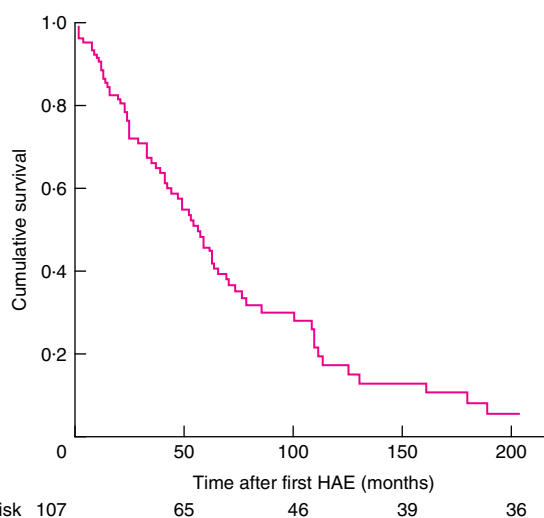


Fig. 1 Median survival after the first hepatic artery embolization (HAE) procedure

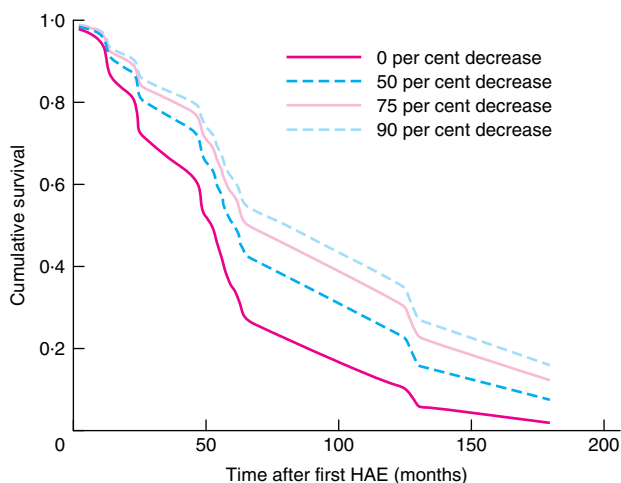


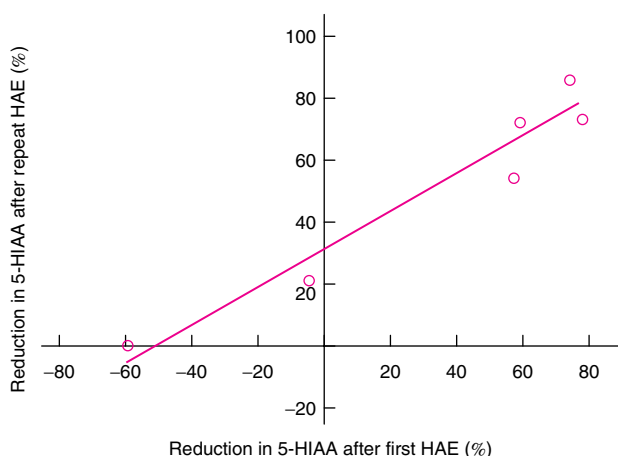
Fig. 2 Predicted survival based on decrease in urinary levels of 5-hydroxyindoleacetic acid. HAE, hepatic artery embolization

further 6-month gain when the reduction was 75 per cent or more (Fig. 2).

There was also a strong correlation between reduced survival and increased AST levels after HAE (HR 1.03 (95 per cent c.i. 1.01 to 1.05);  $P < 0.001$ ).

### Response to repeat embolization

For six of the 19 patients who had repeat HAE on tumour progression, a complete record was available of the changes in urinary 5-HIAA concentration in response to the first and repeat HAE (Fig. 3). The biochemical response to



**Fig. 3** Reduction in 5-hydroxyindoleacetic acid (5-HIAA) levels after first and repeat hepatic artery embolization (HAE) ( $r = 0.968$ ,  $P = 0.002$ )

repeat procedures correlated strongly with the biochemical response to the primary HAE ( $P = 0.002$ ).

## Discussion

In the present series of 107 consecutive patients with liver metastases from midgut carcinoid tumours treated with HAE, the median survival from the first HAE procedure was 56 months. The overall complication rate after HAE was 7.5 per cent, and the fatal complication rate was 1.9 per cent.

This survival compares favourably with recently published results<sup>6</sup>, although patient selection makes direct comparison difficult. The mortality rate reported in other major series was less than 5 per cent, a level proposed to serve as a quality standard<sup>5,6</sup>. In the present study, reductions in the levels of tumour markers (urinary 5-HIAA and plasma CgA) correlated significantly with prolonged survival, and these markers could therefore be used as predictors of long-term outcome. However, the other immediate biochemical change (the increase in AST levels) correlated with reduced survival. It was possible to estimate the gain in survival after successful HAE; a graded survival advantage (6–12 months) correlated with the reduction in tumour-specific markers.

As the biochemical response to the first and repeat HAE procedures was similar, this study also indicates that repeat HAE in patients who fulfil the criteria for tumour progression is of value.

HAE is a palliative treatment option for patients with liver metastases from neuroendocrine tumours<sup>6–9</sup>, and appears especially favourable in patients with midgut

carcinoid tumours<sup>17</sup>. The effect of HAE on hormonal symptoms is well established, but the influence on survival has been unclear. Previous studies have reported on survival benefit<sup>8</sup> or increased estimated survival<sup>13</sup>. In one small series of patients randomized after primary surgery and treatment with interferon, survival was better in those who had HAE<sup>12</sup>.

Efforts have been made to enhance the effect of liver ischaemia. A large non-randomized series indicated that chemotherapy subsequent to HAE increased the effectiveness of treatment in patients with advanced endocrine pancreatic tumours and carcinoids<sup>18</sup>. Hepatic arterial chemoembolization (HACE) combines HAE with liver-targeted intra-arterial cytotoxic agents, such as doxorubicin, streptozotocin, cisplatin and mitomycin C<sup>19–23</sup>. HACE provides relief of hormonal symptoms and often results in long-standing stabilization of the disease, but at the expense of toxicity.

In a previous series, 64 consecutive patients with midgut carcinoid syndrome treated with primary surgery, HAE and somatostatin analogues had a survival rate of 69 per cent at 5 years. At 10 years, survival was still high<sup>11</sup>. These results surpassed those of previous series, which reported 5-year survival rates of between 19 and 40 per cent<sup>18,24–26</sup>.

Mechanisms of action of HAE in addition to tumour ischaemia remain to be established. Natural killer cells increase in the central venous blood of patients with a radiological response to HAE, and individual patients show bilobar tumour regression after unilateral HAE<sup>27</sup>, suggesting that systemic immune mechanisms are involved. As not all patients are responsive to HAE, better selection criteria are still needed to obtain optimal responses to the procedure.

## Acknowledgements

This study was supported by the Swedish Medical Research Council, the Swedish Cancer Society, the I. B. and A. Lundberg Research Foundation, the Assar Gabrielsson Foundation, the Swedish Society of Medicine, the Swedish Society for Medical Research, the Göteborg Medical Society, the King Gustav V Jubilee Clinic Cancer Fund, Sahlgrenska University Hospital Research Funds, Gunvor and Josef Anérs Stiftelse, Axel Linders Stiftelse, Gunnar, Arvid and Elisabeth Nilssons Stiftelse, B. Uhlanders fond, the Serena Ehrenströms Foundation, Wilhelm, Martina Lundgrens Vetenskapsfond and the Selanders Foundation. The authors declare no conflict of interest.

## References

- 1 Cho KJ, Reuter SR, Schmidt R. Effects of experimental hepatic artery embolization on hepatic function. *AJR Am J Roentgenol* 1976; **127**: 563–567.
- 2 Markowitz J, Lotto W, Archibald J, Downie HG. Technique and effects of portacaval anastomosis (Eck fistula). *Surg Gynecol Obstet* 1952; **95**: 407–410.
- 3 Nilsson LA. Therapeutic hepatic artery ligation in patients with secondary liver tumors. *Rev Surg* 1966; **23**: 374–376.
- 4 Chuang VP, Wallace S. Hepatic artery embolization in the treatment of hepatic neoplasms. *Radiology* 1981; **140**: 51–58.
- 5 Ajani JA, Carrasco CH, Wallace S. Neuroendocrine tumors metastatic to the liver. Vascular occlusion therapy. *Ann NY Acad Sci* 1994; **733**: 479–487.
- 6 Gupta S, Yao JC, Ahrar K, Wallace MJ, Morello FA, Madoff DC *et al.* Hepatic artery embolization and chemoembolization for treatment of patients with metastatic carcinoid tumors: the M.D. Anderson experience. *Cancer J* 2003; **9**: 261–267.
- 7 Chamberlain RS, Canes D, Brown KT, Saltz L, Jarnagin W, Fong Y *et al.* Hepatic neuroendocrine metastases: does intervention alter outcomes? *J Am Coll Surg* 2000; **190**: 432–445.
- 8 Coupe M, Levi S, Ellis M, Clarke B, Morris JA, Alstead EA *et al.* Therapy for symptoms in the carcinoid syndrome. *Q J Med* 1989; **73**: 1021–1036.
- 9 Schell SR, Camp ER, Caridi JG, Hawkins IF Jr. Hepatic artery embolization for control of symptoms, octreotide requirements, and tumor progression in metastatic carcinoid tumors. *J Gastrointest Surg* 2002; **6**: 664–670.
- 10 Geterud K, Tylén U, Jansson S, Stenqvist O, Tisell L-E, Ahlman H. Hepatic arterial embolisation in the treatment of the midgut carcinoid syndrome and other advanced endocrine tumours metastatic to the liver. *J Intervent Radiol* 1990; **5**: 69–76.
- 11 Wångberg B, Westberg G, Tylén U, Tisell L, Jansson S, Nilsson O *et al.* Survival of patients with disseminated midgut carcinoid tumors after aggressive tumor reduction. *World J Surg* 1996; **20**: 892–899.
- 12 Jacobsen MB, Hanssen LE, Kolmannskog F, Schrumpf E, Vatn MH, Bergan A. Interferon-alpha 2b, with or without prior hepatic artery embolization: clinical response and survival in mid-gut carcinoid patients. The Norwegian carcinoid study. *Scand J Gastroenterol* 1995; **30**: 789–796.
- 13 Mitty HA, Warner RR, Newman LH, Train JS, Parnes IH. Control of carcinoid syndrome with hepatic artery embolization. *Radiology* 1985; **155**: 623–626.
- 14 Coldwell DM. Hepatic arterial embolization utilizing a coaxial catheter system: technical note. *Cardiovasc Intervent Radiol* 1990; **13**: 53–54.
- 15 Chuang VP. Superselective hepatic tumour embolisation with Tracker-18 catheter. *J Intervent Radiology* 1988; **3**: 69–71.
- 16 Cox DR, Oakes D. *Analysis of Survival Data*. Chapman & Hall: London, 1984.
- 17 Eriksson BK, Larsson EG, Skogseid BM, Löfberg AM, Lörelius LE, Oberg KE. Liver embolizations of patients with malignant neuroendocrine gastrointestinal tumors. *Cancer* 1998; **83**: 2293–2301.
- 18 Moertel CG, Johnson CM, McKusick MA, Martin JK Jr, Nagorney DM, Kvols LK *et al.* The management of patients with advanced carcinoid tumors and islet cell carcinomas. *Ann Intern Med* 1994; **120**: 302–309.
- 19 Drougas JG, Anthony LB, Blair TK, Lopez RR, Wright JK Jr, Chapman WC *et al.* Hepatic artery chemoembolization for management of patients with advanced metastatic carcinoid tumors. *Am J Surg* 1998; **175**: 408–412.
- 20 Perry LJ, Stuart K, Stokes KR, Clouse ME. Hepatic arterial chemoembolization for metastatic neuroendocrine tumors. *Surgery* 1994; **116**: 1111–1116.
- 21 Roche A, Girish BV, de Baère T, Baudin E, Boige V, Elias D *et al.* Trans-catheter arterial chemoembolization as first-line treatment for hepatic metastases from endocrine tumors. *Eur Radiol* 2003; **13**: 136–140.
- 22 Ruzsniwski P, Rougier P, Roche A, Legmann P, Sibert A, Hochlaf S *et al.* Hepatic arterial chemoembolization in patients with liver metastases of endocrine tumors. A prospective phase II study in 24 patients. *Cancer* 1993; **71**: 2624–2630.
- 23 Yao KA, Talamonti MS, Nemcek A, Angelos P, Chrisman H, Skarda J *et al.* Indications and results of liver resection and hepatic chemoembolization for metastatic gastrointestinal neuroendocrine tumors. *Surgery* 2001; **130**: 677–682.
- 24 McDermott EW, Guduric B, Brennan MF. Prognostic variables in patients with gastrointestinal carcinoid tumours. *Br J Surg* 1994; **81**: 1007–1009.
- 25 Modlin IM, Sandor A. An analysis of 8305 cases of carcinoid tumors. *Cancer* 1997; **79**: 813–829.
- 26 Moertel CG. Treatment of the carcinoid tumor and the malignant carcinoid syndrome. *J Clin Oncol* 1983; **1**: 727–740.
- 27 Wångberg B, Ahlman H, Tylén U, Nilsson O, Hermodsson S, Hellstrand K. Accumulation of natural killer cells after hepatic artery embolisation in the midgut carcinoid syndrome. *Br J Cancer* 1995; **71**: 617–618.