

Highlights of the biology of endocrine tumours of the gut and pancreas

G Rindi and C Bordi

Department of Pathology and Laboratory Medicine, Section of Anatomic Pathology, University of Parma, Via Gramsci 14, I-43100 Parma, Italy

(Requests for offprints should be addressed to G.Rindi; Email: guido.rindi@unipr.it)

Abstract

Originating from cells of the diffuse endocrine system the endocrine tumours of the gut and the pancreatic tract are rare entities characterized by a common phenotypic aspect and producing several bioactive substances including growth factors. Two major categories are identified: well-differentiated and poorly differentiated tumours. The clinical behaviour varies ranging from benign to low grade malignant for well-differentiated tumours/carcinomas to high grade malignant for poorly differentiated carcinomas. The two major categories of well-differentiated and poorly differentiated tumours display distinct phenotypes and genetic backgrounds possibly supporting distinct histogenesis. Genetic abnormalities associated with either induction or progression of tumours may vary depending on the site of origin.

Endocrine-Related Cancer (2003) 10 427–436

Histogenesis

It is believed that the endocrine tumours of gut and pancreas originate from the endocrine cells of the diffuse endocrine system (DES). Fifteen cell types producing hormonal peptides or biogenic amines are present in the pancreas and the mucosa of the gastrointestinal (GI) tract (Solcia *et al.* 1998, Rindi *et al.* 1999b). Together with the endocrine cells scattered in other endodermal derivatives such as the thyroid, lung, the biliary tree and urethra, the endocrine cells of the gastroenteropancreatic (GEP) tract belong to the so-called DES. As demonstrated in transgenic mice experiments, transformation of DES cells of gut and pancreas may result in the development of endocrine tumours (Hanahan 1985, Efrat *et al.* 1988, Rindi *et al.* 1990). Since DES cells share a number of antigens with nerve elements ('neuroendocrine markers'), the adjective 'neuroendocrine' has been widely used to describe such cell types and derived tumours. However, the current World Health Organisation (WHO) endocrine tumour classification (Solcia *et al.* 2000) adopted the term 'endocrine' and this definition will be used in this paper.

Diagnosis

Cells variably retaining a proportion of the antigens expressed by the normal DES counterparts comprise the endocrine tumours of gut and pancreas. The positive assessment of endocrine differentiation of tumours requires the

identification of general markers of neuroendocrine differentiation by immunohistochemistry (Bishop *et al.* 1988). Widely used are cytosol markers such as neuron-specific enolase (NSE) (Bishop *et al.* 1982) and protein gene product 9.5 (PGP 9.5) (Rode *et al.* 1985), the membrane-bound neural cell adhesion molecules (NCAM) (Al-Khafaji *et al.* 1998, Lantuejoul *et al.* 1998), or granule markers such as chromogranin A and the ATP-dependent vesicular monoamine transporters 1 and 2 (VMAT1 and VMAT2) (associated with large, dense-core vesicles) (Lloyd & Wilson 1983, Rindi *et al.* 1986, Erickson *et al.* 1996, Kolby *et al.* 1998, Eissele *et al.* 1999, Rindi *et al.* 2000) and synaptophysin (associated with small synaptic-like vesicles) (Jahn *et al.* 1985, Wiedenmann & Franke 1985, Buffa *et al.* 1988). The identification of specific tumour cell types requires hormone immunohistochemistry, searching first for hormones expressed by the DES cells of the anatomical district where the tumour is found and then for 'ectopic' hormones according to specific hyperfunctional syndromes (e.g. gastrin expression in pancreatic endocrine tumours).

Differentiation, histology and behaviour

The recently released WHO classification of the endocrine tumours of the gastroenteropancreatic tract identifies five categories including 'pure' endocrine tumours, mixed exocrine-endocrine tumours and tumour-like lesions (Solcia *et al.* 2000). This classification is based on innovative concepts

and provides a useful framework for the evaluation of the clinical and functional properties of these neoplasms. The concepts governing this classification are: (a) the tumours are subdivided according to the site (stomach, pancreas, duodenum-upper jejunum, ileum-right colon, appendix, and rectum) and cell type of origin; (b) both pathological (such as tumour size, number of mitoses, histologically proven angioinvasion and metastases) and clinical data (such as the occurrence of an associated clinical syndrome) are considered under site-specific 'clinicopathological correlation'; (c) a uniform scheme of classification is used for all sites based on three main categories, the first of which is further subdivided into two subgroups: (i) well-differentiated endocrine tumours, either with benign behaviour (i.i) or with uncertain behaviour – benign or low-grade malignant – (i.ii) at the time of diagnosis; (ii) well-differentiated endocrine carcinomas with low-grade malignant behaviour; (iii) poorly differentiated endocrine carcinomas, with high-grade malignant behaviour.

In general, well-differentiated tumours express diffusely and intensely all the above-mentioned markers of neuroendocrine differentiation, and in particular chromogranin A which appears as the most reliable marker available. Poorly differentiated tumours, on the other hand, display chromogranin A in few, if any, tumour cells, while they retain the expression of synaptophysin, NSE and PGP 9.5 and of the membrane antigen NCAM CD56.

On histological examination, well and poorly differentiated tumours display important differences. In general a bland histology characterizes well-differentiated tumours with trabecular, glandular or solid nest structure (often referred to as organoid), tumour cell monomorphism with absent or mild atypia and low mitotic rate and low proliferative status by Ki-67 (Solcia *et al.* 1998). In contrast, poorly differentiated tumours are mainly solid (though organoid areas may be seen too) with frequent central necrosis, a high degree of cellular atypia, high mitotic index and high proliferative status by Ki-67 (Solcia *et al.* 1998).

Significant differences exist between well and poorly differentiated endocrine tumours regarding their clinical behaviour. Well-differentiated tumours, the largest fraction of endocrine tumours of the digestive tract, may display some low-grade malignant potential. However, only in the presence of proven malignant behaviour, i.e. in synchronous metastasis and/or invasiveness, is the term endocrine carcinoma accepted (Solcia *et al.* 2000). Even so, the life expectancy for patients with metastatic well-differentiated endocrine carcinomas may span many years. In contrast, poorly differentiated endocrine carcinomas (PDEC) are invariably malignant and aggressive, rapidly causing death.

The tumour cell population of well-differentiated tumours may vary significantly. Notably, not all known endocrine cell types have a tumour counterpart so that no tumour is known for secretin, cholecystokinin (CCK),

motilin, gastric inhibitory peptide (GIP) and neurotensin cells. In addition, tumour cells producing different hormones may be present in the same endocrine tumour. This information indicates the high degree of tumour cell differentiation, but has no clinical significance unless associated with an overt clinical syndrome due to hormonal hypersecretion. If this is the case endocrine tumours are currently defined as 'functioning' and it is only in this case that definitions like 'insulinoma' or 'gastrinoma' are acceptable. Most often endocrine tumours are not associated with any specific hyperfunctional symptom and are thus defined as 'non-functioning' (Solcia *et al.* 1998). In general, the cell types composing well-differentiated endocrine tumours reflect their normal counterpart in the organ of origin, e.g. enterochromaffin-like (ECL) cell tumours are only observed in the stomach, insulinomas in the pancreas, etc. In contrast, poorly differentiated endocrine tumours may be present at any site in the gut and pancreas (with the notable exception of the appendix), supporting an origin from an endocrine-committed less-differentiated cell type.

Finally, there is no histological tumour grading for well-differentiated endocrine tumours of the digestive tract, although it has been tentatively developed for pancreatic and gastric tumours (La Rosa *et al.* 1996, Rindi *et al.* 1999a). Further, a number of clinicopathological criteria proved to be useful predictors of malignant behaviour (La Rosa *et al.* 1996, Rindi *et al.* 1999a) and included: tumour size (larger tumours tend to be more aggressive); invasion of nearby tissue (pancreas or appendix) or deep wall invasion; angioinvasion and invasion of perineural spaces; presence of spotty necrosis; overt cell atypia; more than two mitoses in 10 microscopic high power fields (HPF); Ki-67 index of more than 100/10 HPF or more than 2%; loss of chromogranin A immunoreactivity or hormone expression; nuclear p53 protein accumulation; and aneuploid status of tumour cells. These variables should all be considered in assigning a tentative risk class for each specific case. However, the predictive value of such variables remains to be proven for tumours other than those of pancreas and stomach.

Tumour production and functional activity of growth factors

In addition to hormones and biogenic amines, GEP endocrine tumours were frequently found to produce growth factors (GF) that may influence cell proliferation and differentiation either in the tumour cells themselves by an autocrine loop or in the host tissues (Puetzal *et al.* 1993). Although investigation regarding such production is still often preliminary, the data so far generated provide clues for the interpretation of the prominent field responses associated with ileal and gastric carcinoids and causing ileal infarction or severe gastric bleeding, respectively (discussed below).

Growth factors expressed by GEP endocrine tumours

Acidic and basic fibroblast growth factors (aFGF, bFGF)

These are members of a family of heparin binding peptides known to promote angiogenesis and to induce proliferation in other tissues of mesodermal origin (Goldfarb 1990). Moreover, a bFGF-like substance is known to be abnormally elevated in the serum of multiple endocrine neoplasia type 1 (MEN-1) patients (Zimring *et al.* 1993), possibly contributing to the circulating parathyroid mitogenic activity in MEN-1 syndrome (Brandi *et al.* 1986). Consistent expression of aFGF was found in serotonin-producing enterochromaffin (EC) cell tumours of the ileum, appendix, right colon and rectum (La Rosa *et al.* 1997). Such expression was found to correlate with the amount of tumour fibrous stroma, supporting a role for this protein in the tumour-associated fibroblastic response. Expression of bFGF was documented in proliferating ECL cells of hypergastrinaemic patients including both hyperplastic lesions and tumours (Bordi *et al.* 1994) (Fig. 1). The ECL cells, therefore, may represent a potential source of the parathyroid mitogenic factor in patients with MEN-1 syndrome. Indeed, we have found the highest degree of bFGF expression in hyperplastic ECL cells of a MEN-1 patient showing a multiple metastasizing ECL cell tumour (Bordi *et al.* 1997).

Expression of bFGF was also shown in some duodenal gastrinomas (Bordi *et al.* 1998) whereas conflicting results were obtained in midgut EC cell tumours, possibly depending on tumour tissue processing. Indeed, no immunoreactivity was observed in formalin-fixed, paraffin-embedded tumours (La Rosa *et al.* 1997) in contrast with the consistent immunostaining of a large series of frozen, cryosectioned and acetone-fixed tumours (Chaudhry *et al.* 1993). Expression of

the four transcripts of bFGF was documented in cell cultures of an EC cell tumour (Beauchamp *et al.* 1991).

Insulin-like growth factors

The insulin-like growth factor-I (IGF-I) was demonstrated in primary cultures and in tumour extracts of midgut, EC cell tumours (Nilsson *et al.* 1993). IGF-I secretion by cultured tumour cells was inhibited by the somatostatin analogue, octreotide (Ahlman *et al.* 1993). Furthermore, IGF-I-receptors were detected in tumour cells, suggesting an autocrine trophic function for IGF-I in EC cell tumours (Ahlman *et al.* 1993, Nilsson *et al.* 1993).

Platelet-derived growth factor

Platelet-derived growth factor (PDGF), composed of disulphide-bonded A- and B-polypeptide chains, has mitogenic properties for mesenchymal cells (including fibroblasts and smooth muscle cells) and neurons (Chaudhry *et al.* 1992, Ahlman *et al.* 1993). PDGF-B and PDGF- α receptors were found to be expressed by either tumour cells or stroma of most midgut, EC cell tumours (Chaudhry *et al.* 1992). The occurrence of PDGF- α receptors, which bind to either A or B chains, in tumour and stromal cells supports both autocrine tumour cell stimulation and induction of stromal proliferation in this type of tumour.

Transforming growth factor- α (TGF- α)

This 50-amino-acid polypeptide stimulates cell growth after binding to epidermal growth factor receptors (EGFR). TGF- α and EGFR were shown to be ubiquitously and extensively expressed by gut endocrine tumours, similar to other extraintestinal endocrine tumours (Beauchamp *et al.* 1991, Nilsson *et al.* 1995). The effectiveness of the EGFR of tumour cells to respond to the TGF- α autocrine stimulus was

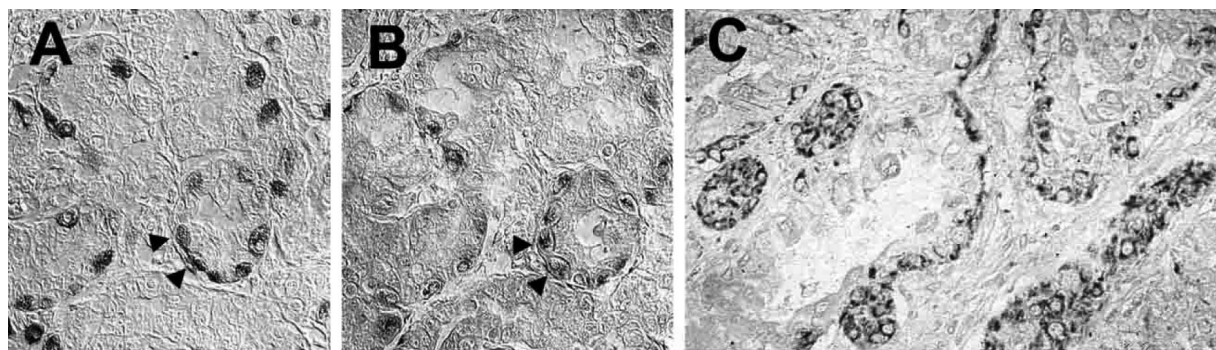


Figure 1 bFGF expression in gastric ECL cells and derived growths. Chain-forming hyperplastic ECL cells positive for chromogranin A (A) express bFGF in consecutive serial sections (B); the arrowheads indicate cells positive for both antigens. (C) bFGF is heavily expressed in hyperplastic linear and micronodular ECL cell changes (upper left) and ECL cell tumour (lower right) in the gastric mucosa of a patient with Zollinger-Ellison and MEN-1 syndrome. The immunoperoxidase, ABC method was used.

documented *in vitro* (Nilsson *et al.* 1995). TGF- α expression was not specific for a given tumour type, being observed in ECL cell tumours of the stomach, somatostatin cell tumours of the duodenum, EC cell tumours of the ileum and appendix and L cell tumours of the rectum (Krishnamurthy & Dayal 1997). It was found to be unrelated to the tumour size or to the occurrence of metastases but was more frequent in tumours infiltrating the *muscularis propria* than in those limited to the mucosa/submucosa, suggesting a role for local invasion (Krishnamurthy & Dayal 1997). In pancreatic endocrine tumours different patterns ranging from full expression of TGF- α and of the complete EGFR molecule to the expression of only one of the two antigens or to the absence of both were found (Srivastava *et al.* 2001). These patterns showed no correlation with size, functional status or biological behaviour of the tumours, indicating no role for TGF- α in tumour progression.

Transforming growth factor- β (TGF- β)

Expression of TGF- β has been consistently demonstrated in midgut EC cell tumours (Beauchamp *et al.* 1991, Ahlman *et al.* 1993, Chaudhry *et al.* 1994) whereas expression of TGF- β receptor and of the latent TGF- β binding protein (LTBP) was demonstrated in the tumour stroma (Chaudhry *et al.* 1994).

Neurotrophic factor(s)

Production of factors having neurotrophic properties was elegantly demonstrated by transplants of cells of gastrointestinal endocrine tumours in the anterior eye chamber of immunosuppressed rats that elicited growth of sympathetic nerves from the host iris (Nilsson *et al.* 1984, Theodorsson *et al.* 1989). Moreover, co-cultures of midgut, EC cell tumour cells and rat foetal cholinergic neurons allowed survival of neurons with pronounced extension of neurites whereas no neuron survival was obtained in cultures of neurons alone (Wigander *et al.* 1991). The relevant, transferable neurotrophic factor, however, has not been identified yet. Northern blot analysis and specific bioassays proved negative for nerve growth factor (Ahlman *et al.* 1993).

Potential *in vivo* effects of growth factors

Several features associated with GEP endocrine tumours are consistent with a functional response of different host tissues to tumour production and release of growth factors.

Among the various tissues involved, proliferation of smooth muscle cells has been documented in association with ECL cell tumours of the stomach (Bordi *et al.* 1995). The change includes hypertrophy of the *muscularis mucosae*, especially where infiltrated by the tumours, proliferation of intratumoral stromal smooth muscle cells originating from the *muscularis mucosae*, mostly associated with tumour invasion of the submucosa, and the occurrence of frequent, prominent aggregates of smooth muscle cells in the *lamina*

propria of the antral mucosa. bFGF, a potent mitogen for smooth muscle cells, locally released by ECL cell tumours and their precursor lesions (Bordi *et al.* 1994), may be responsible for these smooth muscle cell abnormalities.

In ileal EC cell tumours, as originally described by McNeal (1971), the muscle layers of the ileal wall, in particular the inner one, show hypertrophy sharply limited to the area of tumour penetration. Among the growth factors found to be expressed by this type of tumour, aFGF, bFGF and PDGF-B cause proliferation of smooth muscle cells (Chaudhry *et al.* 1992, Ahlman *et al.* 1993).

Combined smooth muscle and neural cell proliferation, originally described as neuromuscular hyperplasia by Masson (1928), is frequently found in association with EC cell tumours of the appendix, suggesting a potential paracrine influence of extraepithelial normal and tumour endocrine cells (Olsen & Holck 1987). TGF- α , the only growth factor so far identified in endocrine tumours of the appendix (Krishnamurthy & Dayal 1997), has neurotrophic effects and its receptors have been demonstrated in neurons (Ahlman *et al.* 1993). Striking hypertrophy of nerves running along areas of tumour infiltration has been described in ileal EC cell tumours (Bordi *et al.* 1998). Among the potential candidate growth factors are IGF-I, TGF- α , aFGF and PDGF, all with neurotrophic effects. Neurons are known to possess receptors for the three former peptides (Ahlman *et al.* 1993), whereas PGDF- α receptors were found in enteric nerve bundles including those close to tumour tissue (Chaudhry *et al.* 1992).

Ileal EC cell tumours are also characterized by the important fibroblastic response elicited by the tumour infiltration of the mesentery and peritoneum. This response may frequently result in buckling of the mesenteric border of the bowel wall, leading to bowel twisting and, eventually, to intestinal obstruction (Moertel *et al.* 1961). Furthermore, the EC cell tumours are associated with the well-known proliferation of subendocardial fibrous tissue in the right heart, leading to the cardiomyopathy that is an integral part of the carcinoid syndrome (Lester & Gotlieb 1991). The demonstration of TGF- β receptor and of LTBP in the stroma of such tumours (Chaudhry *et al.* 1994) makes TGF- β a potential candidate molecule for the local and distant response of fibroblasts to midgut EC cell tumours. Interestingly, TGF- β s (β 1 and β 3 in particular) were found to be expressed by fibroblasts in the subendocardial fibrotic plaques of carcinoid heart disease, suggesting a role in the progressive deposition of matrix proteins typical of this serious complication of the carcinoid syndrome (Waltenberger *et al.* 1993).

A specific feature of ileal and jejunal well-differentiated endocrine tumours is the diffuse proliferation of both intimal and adventitial elastic tissue in large arterial and venous vessels of the mesenteric pedicle, often called vascular elastosis (Anthony & Drury 1970, Qizilbash 1977) and sometimes associated with proliferation of extravascular elastic fibres

within the bowel wall (Qizilbash 1977). Not infrequently, vascular elastosis may cause ischaemic changes or even intestinal infarction. Little is known about the role of growth factors on elastic tissue, so no suggestion can be made as to the tumour factors responsible for the associated elastosis. In addition, vascular malformations and/or proliferations have also been observed in ECL cell gastric tumours (Roncoroni *et al.* 1997). These lesions may cause severe, life-threatening gastric bleeding. bFGF produced by ECL cell tumours (Bordi *et al.* 1994) is the most obvious candidate for this vascular response.

Finally, it is noteworthy that local responses of host tissues similar to those observed in gastrointestinal endocrine tumours have not, so far, been reported in pancreatic endocrine tumours.

Genetic background

Molecular data on the endocrine tumours are rapidly accumulating although the search for the genetic basis of tumour development is still elusive. In addition, the correct interpretation of the data is still suffering from the frequent lack of basic information such as the precise anatomical location, tumour cell type and clinical behaviour of the investigated tumours. In general, pancreatic endocrine tumours have been more extensively investigated than their gastrointestinal counterparts.

A great impulse for the study of the genetic background of endocrine tumours was given by the identification of the MEN-1 syndrome. Located on chromosome 11q13 and found to act as a tumour suppressor gene (Larsson *et al.* 1988), the MEN-1 gene was recently identified and sequenced (Chandrasekharappa *et al.* 1997). The nuclear localisation of the gene product named 'menin' suggests that it may act either in the regulation of transcription and DNA replication or in the cell cycle, likely interacting with the AP-1 transcriptional factor JunD (Agarwal *et al.* 1999) and with nuclear factor (NF)- κ B proteins (Heppner *et al.* 2001). In patients with MEN-1, an inherited germ line mutation of the MEN-1 gene is associated with loss of function of the somatic allele by either chromosomal deletion (loss of heterozygosity, LOH) or point mutation, resulting in endocrine tumour development. Considerable amounts of data indicate that the MEN-1 gene is inactivated in at least a fraction of sporadic endocrine tumours of the foregut, making the MEN-1 gene the most important gene involved in the induction of these tumours. More than 300 different mutations of the *MEN1* gene have been identified, none of them being associated with a specific tumour phenotype (Brandi *et al.* 2002). In addition up to 30% of MEN-1 patients still lack the MEN-1 gene mutation in the published series (Brandi *et al.* 2002). Below, we will focus on different genes involved in the induction and progression of endocrine tumours for the gastroenteropancreatic tract.

Tumour induction

Pancreas

Solid data have been generated on the allelic losses (LOH) at chromosome 11q13 region including the locus of the *MEN1* gene in either familial or sporadic pancreatic endocrine tumours (PET). On the basis of a literature survey of 172 cases (Rindi *et al.* 2001), 11q13 LOH is found in 46% of sporadic PET. This finding is confirmed by a genome-wide investigation on non-functioning PET either by comparative genomic hybridization (CGH) (Speel *et al.* 1999) or high resolution allelotyping (Rigaud *et al.* 2001). When the LOH analysis was extended to the more telomeric markers in 11q, it was found that the allelic loss consistently and continuously spanned to 11qter (D'Adda *et al.* 2002). This observation indicates a mechanism of gene inactivation via chromosomal breakage and complete loss of 11q and supports the hypothesis of a potential additional oncosuppressor gene in 11q distal to the MEN-1 gene, that may cooperate with the latter or replace it in the pathogenesis of PET (Eubanks *et al.* 1994, Chakrabarti *et al.* 1998, D'Adda *et al.* 1999b). The abnormality rate decreases when searching for *MEN1* gene mutation. Of 35 gastrinomas investigated, 15 (43%) were mutated, in sharp contrast with only 6 mutated insulinomas out of 62 insulinomas investigated (10%) (Rindi *et al.* 2001). The mutation rate of non-functioning (NF) tumours was 15% in 26 cases investigated overall (Rindi *et al.* 2001), while a recent study of 30 NF tumours showed 26% of cases harbouring MEN-1 mutations (Moore *et al.* 2001a). These data support the relevant role played by the *MEN1* gene in the pathogenesis of about one third of pancreatic endocrine tumours. However, this observation implies that gene(s) other than *MEN1* may be involved.

A recent CGH study on small, 'initial', tumours (< 2 cm in diameter) (Speel *et al.* 2001) showed considerable variations in the functioning versus non functioning pancreatic endocrine tumours with 9q gain in 46.4% of functioning tumours and, in particular, in 50% of insulinomas, with the common region of involvement (CRI) at 9q34. These alterations in non-functioning tumours were, however, detected in a background of diffuse genetic instability with at least 10 genetic chromosome arm aberrations per tumour, making the significance of the individual change difficult to evaluate. Overexpression of cyclin D1 was found by both immunohistochemistry and Northern analysis in 43% of PET showing no correlation with any specific tumour phenotype (Chung *et al.* 2000). Its occurrence in both benign and advanced lesions suggested an early event in tumour pathogenesis. Finally, an unusually high rate of LOH in chromosome 22q (93%) was observed in both benign and malignant insulinomas, suggesting a type-specific tumour suppressor gene in this region (Wild *et al.* 2001).

Gut

In general, the endocrine tumours of the gastrointestinal tract have been poorly studied with frequent lack of identification

of the tumour cell-type or of analysis of gene mutation. Significant differences, however, are emerging between tumours of the region deriving from the primitive foregut (stomach, duodenum and upper jejunum) and those deriving from the midgut and hindgut (ileum, appendix and large intestine). Such differences reflect the different involvement of the respective tumours in the MEN-1 syndrome that is restricted to gastric ECL cell tumours of the stomach and duodenal gastrinomas. In these types of tumours 11q13 LOH has been documented both in familial and sporadic cases (Debelenko *et al.* 1997a,b, D'Adda *et al.* 1999b). For gastric ECL cell tumours, a literature survey disclosed 75% of losses at the MEN-1 locus in 23 familial cases versus 41% in 46 sporadic cases (Rindi *et al.* 2001). In addition, *MEN1* gene allelic loss was observed in four out of five poorly differentiated endocrine carcinomas of the stomach (Bordi *et al.* 1997, D'Adda *et al.* 1999b, Fujii *et al.* 1999). For duodenal gastrinomas and local nodes a similar frequency of 11q13 LOH was observed in both familial and sporadic forms (28% and 25% respectively) while MEN-1 gene mutation occurred in 22 out of 67 sporadic cases (33%) (Rindi *et al.* 2001). In contrast, tumours from more distal regions of the intestinal tract only rarely display MEN-1 gene alterations. A recent study from our laboratory (D'Adda *et al.* 2002), including 16 ileal, 6 appendicular and 3 rectal well differentiated endocrine tumours, showed an overall LOH rate of 9% of informative 11q13 microsatellites investigated. MEN-1 gene mutation was found in only one of twelve midgut endocrine tumours investigated (Toliat *et al.* 1997, Görtz *et al.* 1999).

Accumulating evidence indicates an important role for chromosome 18 in the induction of midgut well-differentiated endocrine tumours. Indeed, the imbalance of this chromosome, with frequent loss of 18q, is the most frequent abnormality detected by both CGH and LOH in well-differentiated midgut endocrine tumours and appears to be typical of these neoplasms (Zhao *et al.* 2000, Kytola *et al.* 2001, Löllgen *et al.* 2001, Tonnie *et al.* 2001). In a combined CGH/LOH study of 18 classical midgut EC cell tumours, losses at 18q22-qter were seen in 67% of cases (Kytola *et al.* 2001) whereas a genome-wide LOH screening of 8 tumours showed 18q21 losses to be very frequent (88% of cases) as well as specific alterations of these neoplasms (Löllgen *et al.* 2001). These alterations were telomeric to the loci of the genes SMAD2, SMAD4 and DCC which are largely involved in colorectal cancer.

Tumour progression

Pancreas

Several studies aimed at assessing the relationship between genetic defects and tumour progression or malignancy have been undertaken. Most of these studies, however, refer to a small series of cases and their results await confirmation by investigations on a larger series. Deletion of either arm of

chromosome 1 was found in 10 out of 17 metastatic pancreatic endocrine tumours with no tumour type prevalence (Ebrahimi *et al.* 1999). This finding, however, was not confirmed in CGH and genome-wide allelotyping studies (Speel *et al.* 1999, Rigaud *et al.* 2001). Allelic loss at 3p25 centromeric to the locus of the von Hippel-Lindau syndrome gene has been identified by Chung *et al.* (1997) and found to be associated with malignancy. The association of 3p loss and metastatic disease was further supported by a CGH study of 44 tumours of different types (Speel *et al.* 1999) and by a recent large study of 99 pancreatic endocrine tumours (Barghorn *et al.* 2001a) with 3p LOH in 76.7% of metastasizing versus 41.5% of non-metastasizing tumours. The frequent occurrence of 6q allelic loss for 6p has been documented in pancreatic tumours although its association with malignancy and tumour progression was observed by one group (Speel *et al.* 1999, Barghorn *et al.* 2001b) but not confirmed by another (Rigaud *et al.* 2001). Barghorn *et al.* (2001b) narrowed down two common regions of allelic deletion at 6q22.1 and 6q23–24 respectively, showing that isolated 6q LOH could also be found in benign tumours suggesting that the potential for malignant progression may occur at an early stage.

p53 mutations are rarely found in well-differentiated endocrine tumours (Lohmann *et al.* 1993b, Pellegata *et al.* 1994, Moore *et al.* 2001b). However, LOH at 17p13 was reported in 25% of cases and was associated with malignancy in one study (Beghelli *et al.* 1998). The lack of concomitant detectable *p53* mutations and a detailed 17p allelotyping led these authors to suggest that an additional, malignancy-involved tumour suppressor gene may occur in 17p telomeric to *p53*. *p53* nuclear hyperexpression/accumulation was frequently observed in poorly differentiated cases (La Rosa *et al.* 1996).

Allelic loss for markers on chromosome X was demonstrated in 60% of the informative loci investigated in malignant PET versus a rate of 4.5% in benign PET ($P < 0.0001$) (Pizzi *et al.* 2002). Interestingly, in one case more severe changes were shown in the liver metastasis than in the primary tumour, a finding further supporting the role for the inactivation of tumour suppressor gene(s) on the X-chromosome in the acquisition of a more aggressive phenotype by PET. Scarpa and his group extended the analysis to chromosome Y in male patients and found a significant association of sex chromosome losses with malignant features such as metastases, local invasion and high Ki-67 proliferation rate as well as shorter survival (Missiaglia *et al.* 2002).

Finally, the accumulation of genetic defects in different oncosuppressor genes reasonably plays a significant role in tumour progression and malignancy. The frequency of LOH for markers of seven oncosuppressor genes was significantly higher in malignant (40%) than in benign (17%) endocrine tumours (Beghelli *et al.* 1998). A paired CGH study of primary tumours and their metastases with a control group of

non-metastatic tumours further supported this view with 17.3 mean genomic aberrations in metastases, 12.5 in their primary tumours and 4.5 in non-metastatic cases (Zhao *et al.* 2001). Finally, in non-functioning pancreatic tumours two subgroups with either a high or a low frequency of chromosomal markers loss (fractional allelic loss, FAL) were identified by genome-wide allelotyping analysis (Rigaud *et al.* 2001). These genetic phenotypes correlated with the ploidy status. Low-FAL tumours were diploid whereas high-FAL tumours were aneuploid, a condition found to be associated with a significantly poorer clinical outcome (Rigaud *et al.* 2001).

Gut

The available data are particularly scanty regarding gastric endocrine tumours. In a study of such tumours, extensive losses of X-chromosomal markers were present in all 4 malignant tumours (100% of informative markers), but were virtually absent in the 29 benign neoplasms investigated (D'Adda *et al.* 1999a). Such an association was not found in 17 midgut endocrine tumours that showed a very low frequency of X-chromosome allelic losses in malignant tumours (15% of informative markers investigated) and no losses in benign tumours. These findings support an association between X-chromosome LOH and malignancy in foregut endocrine tumours, in keeping with data obtained in the pancreas (Pizzi *et al.* 2002). A CGH study of 13 primary and 5 metastatic classical midgut carcinoids showed that losses at 16q21-qter and gains at 4p14-pter were rare/absent in primary tumours and were extensively present in most metastatic tissues investigated (Kytola *et al.* 2001). *p53* mutations are rarely seen in well-differentiated tumours at any gut site (Lohmann *et al.* 1993a), although *p53* protein hyperexpression/accumulation has been reported in poorly differentiated carcinomas of the stomach (Rindi *et al.* 1999a). In addition, LOH for *p53* and markers on 18q were observed in poorly differentiated endocrine carcinomas of the large intestine with *p53* nuclear protein hyperexpression/accumulation and gene mutation (Vortmeyer *et al.* 1997, Ubiali *et al.* 2001).

Concluding remarks

The endocrine tumours of gut and pancreas display substantial differences in terms of phenotype and behaviour. Several variables including angioinvasion, the mitotic index and the overexpression/accumulation of *p53* protein may be useful predictors of survival for patients with gastric and pancreatic tumours. More work is required to confirm their potential utility in tumours of the intestine. Information on the molecular basis of endocrine tumours is limited overall. The *MEN1* gene appears to be involved in tumour induction of both poorly differentiated and well-differentiated tumours, at least for those of foregut derivation. Other tumour suppressor genes on chromosomes 3p25, 9p21, 18q21 and X have been

suggested to participate in the mechanism of endocrine tumour induction and/or progression. In any case, a complex picture of multiple gene involvement is emerging. Extensive investigation on a large tumour series are needed to better delineate the data so far available.

Acknowledgements

This work was supported by grants from MURST (COFIN 01), AIRC Milan, and the University of Parma.

References

- Agarwal SK, Guru SC, Heppner C, Erdos MR, Collins RM, Park SY, Saggari S, Chandrasekharappa SC, Collins FS, Spiegel AM, Marx SJ & Burns AL 1999 Menin interacts with the AP1 transcription factor JunD and represses JunD-activated transcription. *Cell* **96** 143–152.
- Ahlman H, Wangberg B & Nilsson O 1993 Growth regulation in carcinoid tumors. *Endocrinology and Metabolism Clinics of North America* **22** 889–915.
- Al-Khafaji B, Noffsinger AE, Miller MA, DeVoe G, Stemmermann GN & Fenoglio-Preiser C 1998 Immunohistologic analysis of gastrointestinal and pulmonary carcinoid tumors. *Human Pathology* **29** 992–999.
- Anthony PP & Drury RAB 1970 Elastic vascular elastosis of mesenteric blood vessels in argentaffin carcinoma. *Journal of Clinical Pathology* **23** 110–118.
- Barghorn A, Komminoth P, Bachmann D, Rutimann K, Saremaslani P, Muletta Feurer S, Perren A, Roth J, Heitz PU & Speel EJM 2001a Deletion at 3p25.3-p23 is frequently encountered in endocrine pancreatic tumours and is associated with metastatic progression. *Journal of Pathology* **194** 451–458.
- Barghorn A, Speel EJM, Farspour B, Saremaslani P, Schmid S, Perren A, Roth J, Heitz PU & Komminoth P 2001b Putative tumor suppressor loci at 6q22 and 6q23-q24 are involved in the malignant progression of sporadic endocrine pancreatic tumors. *American Journal of Pathology* **158** 1903–1911.
- Beauchamp RD, Coffey RJ, Lyons RM, Perkett EA, Townsend CM & Moses HL 1991 Human carcinoid cell production of paracrine growth factors that can stimulate fibroblast and endothelial cell growth. *Cancer Research* **51** 5253–5260.
- Beghelli S, Pelosi G, Zamboni G, Falconi M, Iacono C, Bordi C & Scarpa A 1998 Pancreatic endocrine tumours: evidence for a tumour suppressor pathogenesis and for a tumour suppressor gene on chromosome 17p. *Journal of Pathology* **186** 41–50.
- Bishop AE, Polak JM, Facer P, Ferri GL, Marangos PJ & Pearce AG 1982 Neuron specific enolase: a common marker for the endocrine cells and innervation of the gut and pancreas. *Gastroenterology* **83** 902–915.
- Bishop AE, Power RF & Polak JM 1988 Markers for neuroendocrine differentiation. *Pathology Research and Practise*, **183** 119–128.
- Bordi C, Falchetti A, Buffa R, Azzoni C, D'Adda T, Caruana P, Rindi G & Brandi ML 1994 Production of basic fibroblast growth factor by gastric carcinoid tumors and their putative cells of origin. *Human Pathology* **25** 175–180.
- Bordi C, Caruana P, D'Adda T & Azzoni C 1995 Smooth muscle cell abnormalities associated with gastric ECL cell carcinoids. *Endocrine Pathology* **6** 103–113.

- Bordi C, Falchetti A, Azzoni C, D'Adda T, Canavese G, Guariglia A, Santini D, Tomassetti P & Brandi ML 1997 Aggressive forms of gastric neuroendocrine tumors in multiple endocrine neoplasia type I. *American Journal of Surgical Pathology* **21** 1075–1082.
- Bordi C, D'Adda T, Azzoni C, Canavese G & Brandi ML 1998 Gastrointestinal endocrine tumors: recent developments. *Endocrine Pathology* **9** 99–115.
- Brandi ML, Aurbach GD, Fitzpatrick LA, Quarto R, Spiegel AM, Blizotes MM, Norton JA, Doppman JL & Marx SJ 1986 Parathyroid mitogenic activity in plasma from patients with familial multiple endocrine neoplasia type 1. *New England Journal of Medicine* **314** 1287–1293.
- Brandi ML, Bordi C, Tonelli F, Falchetti A & Marx SJ 2002 Multiple endocrine neoplasia type 1. In *Principles of Bone Biology*, pp 783–797. Eds JP Bilezikian, LG Raisz & GA Rodan. San Diego: Academic Press.
- Buffa R, Rindi G, Sessa F, Gini A, Capella C, Jahn R, Navone F, De Camilli P & Solcia E 1988 Synaptophysin immunoreactivity and small clear vesicles in neuroendocrine cells and related tumours. *Molecular and Cellular Probes* **1** 367–381.
- Chakrabarti R, Srivatsan ES, Wood TF, Eubanks PJ, Ebrahimi S, Gatti RA, Passaro EP & Sawicki MP 1998 Deletion mapping of endocrine tumors localizes a second tumor suppressor gene on chromosome band 11q13. *Genes, Chromosomes and Cancer* **22** 130–137.
- Chandrasekharappa SC, Guru SC, Manickam P, Olufemi SE, Collins FS, Emmert-Buck MR, Debelenko LV, Zhuang ZP, Lubensky IA, Liotta LA *et al.* 1997 Positional cloning of the gene for multiple endocrine neoplasia-type 1. *Science* **276** 404–407.
- Chaudhry A, Papanicolau V, Öberg K, Heldin C-H & Funa K 1992 Expression of platelet-derived growth factor and its receptors in neuroendocrine tumors of the digestive system. *Cancer Research* **52** 1006–1012.
- Chaudhry A, Funa K & Öberg K 1993 Expression of growth factor peptides and their receptors in neuroendocrine tumors of the digestive system. *Acta Oncologica* **32** 107–114.
- Chaudhry A, Öberg K, Gobl A, Heldin C-H & Funa K 1994 Expression of transforming growth factors β 1, β 2, β 3 in neuroendocrine tumors of the digestive system. *Anticancer Research* **14** 2085–2091.
- Chung DC, Smith AP, Louis DN, Graeme-Cook F, Warshaw AL & Arnold A 1997 A novel pancreatic endocrine tumor suppressor gene locus on chromosome 3p with clinical prognostic implications. *Journal of Clinical Investigation* **100** 404–410.
- Chung DC, Brown SB, Graeme Cook F, Seto M, Warshaw AL, Jensen RT & Arnold A 2000 Overexpression of cyclin D1 occurs frequently in human pancreatic endocrine tumors. *Journal of Clinical Endocrinology and Metabolism* **85** 4373–4378.
- D'Adda T, Candidus S, Bordi C & Höffler H 1999a Gastric neuroendocrine neoplasms: tumor clonality and malignancy associated large X-chromosomal deletions. *Journal of Pathology* **189** 394–401.
- D'Adda T, Keller G, Bordi C & Höffler H 1999b Loss of heterozygosity at 11q13–14 regions in gastric neuroendocrine tumors not associated with multiple endocrine neoplasia type 1 syndrome. *Laboratory Investigation* **79** 671–677.
- D'Adda T, Pizzi S, Azzoni C, Bottarelli L, Crafa P, Pasquali C, Davoli C, Corleto VD, Delle Fave G & Bordi C 2002 Different patterns of 11q allelic losses in digestive endocrine tumors. *Human Pathology* **33** 322–329.
- Debelenko LV, Emmert-Buck MR, Zhuang ZP, Epshteyn E, Moskaluk CA, Jensen RT, Liotta LA & Lubensky IA 1997a The multiple endocrine neoplasia type I gene locus is involved in the pathogenesis of type II gastric carcinoids. *Gastroenterology* **113** 773–781.
- Debelenko LV, Zhuang ZP, Emmert-Buck MR, Chandrasekharappa SC, Manickam P, Guru SC, Marx SJ, Skarulis MC, Spiegel AM, Collins FS, Jensen RT, Liotta LA & Lubensky IA 1997b Allelic deletions on chromosome 11q13 in multiple endocrine neoplasia type 1-associated and sporadic gastrinomas and pancreatic endocrine tumors. *Cancer Research* **57** 2238–2243.
- Ebrahimi SA, Wang EH, Wu A, Schreck RR, Passaro E & Sawicki MP 1999 Deletion of chromosome 1 predicts prognosis in pancreatic endocrine tumors. *Cancer Research* **59** 311–315.
- Efrat S, Teitelman G, Anwar M, Ruggiero D & Hanahan, D 1988 Glucagon gene regulatory region directs oncoprotein expression to neurons and pancreatic alpha cells. *Neuron* **1** 605–613.
- Eissele R, Anlauf M, Schafer MKH, Eiden LE, Arnold R & Weihe E 1999 Expression of vesicular monoamine transporters in endocrine hyperplasia and endocrine tumors of the oxyntic stomach. *Digestion* **60** 428–439.
- Erickson JD, Schäfer MK, Bonner TI, Eiden LE & Weihe E 1996 Distinct pharmacological properties and distribution in neurons and endocrine cells of two isoforms of the human vesicular monoamine transporter. *PNAS* **93** 5166–5171.
- Eubanks PJ, Sawicki MP, Samara GJ, Gatti R, Nakamura Y, Tsao D, Johnson C, Hurwitz M, Wan Y-JY & Passaro E 1994 Putative tumor-suppressor gene on chromosome 11 is important in sporadic endocrine tumor formation. *American Journal of Surgery* **167** 180–185.
- Fujii T, Kawai T, Saito K, Hishima T, Hayashi Y, Imura J, Hironaka M, Hosoya Y, Koike M & Fukayama, M 1999 MEN1 gene mutations in sporadic neuroendocrine tumors of foregut derivation. *Pathology International* **49** 968–973.
- Goldfarb M 1990 The fibroblast growth factor family. *Cell Growth and Differentiation* **1** 439–445.
- Görtz B, Roth J, Krähenmann A, de Krijger RR, Muletta-Feurer S, Rütimann K, Saremaslani P, Speel EJM, Heitz PU & Komminoth P 1999 Mutations and allelic deletions of the MEN1 gene are associated with a subset of sporadic endocrine pancreatic and neuroendocrine tumors and not restricted to foregut neoplasms. *American Journal of Pathology* **154** 429–436.
- Hanahan D 1985 Heritable formation of pancreatic beta-cell tumours in transgenic mice expressing recombinant insulin/simian virus 40 oncogenes. *Nature* **315** 115–122.
- Heppner C, Bilimoria KY, Agarwal SK, Kester MB, Whitty LJ, Guru SC, Chandrasekharappa SC, Collins FS, Spiegel AM, Marx SJ & Burns AL 2001 The tumor suppressor protein menin interacts with NF-kappa B proteins and inhibits NF-kappa B-mediated transactivation. *Oncogene* **20** 4917–4925.
- Jahn R, Schiebler W, Ouimet C & Greengard P 1985 A 38 000-dalton membrane protein (p38) present in synaptic vesicles. *PNAS* **82** 4137–4141.
- Kolby L, Wangberg B, Ahlman H, Jansson S, Forssell-Aronsson E, Erickson JD & Nilsson O 1998 Gastric carcinoid with histamine production, histamine transporter and expression of somatostatin receptors. *Digestion* **59** 160–166.
- Krishnamurthy S & Dayal Y 1997 Immunohistochemical expression of transforming growth factor alpha and epidermal growth factor receptor in gastrointestinal carcinoids. *American Journal of Surgical Pathology* **21** 327–333.

- Kytola S, Hoog A, Nord B, Cedermark B, Frisk T, Larsson C & Kjellman M 2001 Comparative genomic hybridization identifies loss of 18q22-qter as an early and specific event in tumorigenesis of midgut carcinoids. *American Journal of Pathology* **158** 1803–1808.
- La Rosa S, Sessa F, Capella C, Riva C, Leone BE, Klersy C, Rindi G & Solcia E 1996 Prognostic criteria in nonfunctioning pancreatic endocrine tumours. *Virchows Arch* **429** 323–333.
- La Rosa S, Chiaravalli AM, Capella C, Uccella S & Sessa F 1997 Immunohistochemical localization of acidic fibroblast growth factor in normal human enterochromaffin cells and related gastrointestinal tumours. *Virchows Archiv* **430** 117–124.
- Lantuejoul S, Moro D, Michalides RJ, Brambilla C & Brambilla E 1998 Neural cell adhesion molecules (NCAM) and NCAM-PSA expression in neuroendocrine lung tumors. *American Journal of Surgical Pathology* **22** 1267–1276.
- Larsson C, Skogseid B, Öberg K, Nakamura Y & Nordenskjöld M 1988 Multiple endocrine neoplasia type 1 gene maps to chromosome 11 and is lost in insulinoma. *Nature* **332** 85–87.
- Lester WM & Gotlieb AI 1991 The cardiovascular system. In *Functional Endocrine Pathology*, vol. 2, pp 724–747. Eds K Kovacs & SL Asa. Boston: Blackwell.
- Lloyd RV & Wilson BS 1983 Specific endocrine tissue marker defined by a monoclonal antibody. *Science* **222** 628–630.
- Lohmann D, Putz B, Reich U, Böhm J, Prauer H & Hofler H 1993a Mutational spectrum of the p53 gene in human small-cell lung cancer and relationship to clinicopathological data. *American Journal of Pathology* **142** 907–915.
- Lohmann DR, Funk A, Niedermeyer HP, Haupel S & Hofler H 1993b Identification of p53-gene mutations in gastrointestinal and pancreatic carcinoids by nonradioisotopic SSCA. *Virchows Archiv (B)* **64** 293–296.
- Löflgen RM, Hessman O, Szabo E, Westin G & Åkerström G 2001 Chromosome 18 deletions are common events in classical midgut carcinoid tumors. *International Journal of Cancer* **92** 812–815.
- Masson P 1928 Carcinoids (argentaffin cell tumors) and nerve hyperplasia of the appendicular mucosa. *American Journal of Pathology* **4** 181–211.
- McNeal JE 1971 Mechanism of obstruction in carcinoid tumors of the small intestine. *American Journal of Clinical Pathology* **56** 454–458.
- Missiaglia E, Moore PS, Williamson J, Lemoine NR, Falconi M, Zamboni G & Scarpa A 2002 Sex chromosome anomalies in pancreatic endocrine tumors. *International Journal of Cancer* **98** 532–538.
- Moertel CG, Sauer WG, Dockerty MB & Baggenstoss AH 1961 Life history of the carcinoid tumor of the small intestine. *Cancer* **14** 901–912.
- Moore PS, Missiaglia E, Antonello D, Zamo A, Zamboni G, Corleto V, Falconi M & Scarpa A 2001a Role of disease-causing genes in sporadic pancreatic endocrine tumors: MEN1 and VHL. *Genes, Chromosomes and Cancer* **32** 177–181.
- Moore PS, Orlandini S, Zamboni G, Capelli P, Rigaud G, Falconi M, Bassi C, Lemoine NR & Scarpa A 2001b Pancreatic tumours: molecular pathways implicated in ductal cancer are involved in ampullary but not in exocrine nonductal or endocrine tumorigenesis. *British Journal of Cancer* **84** 253–262.
- Nilsson O, Dahlström A, Grönstad K-O, Rosengren L, Briving C, Skolnik G & Ahlman H 1984 Successful transplantation of a human midgut carcinoid tumour to the anterior eye chamber of the rat. *Acta Physiologica Scandinavica* **120** 317–319.
- Nilsson O, Wangberg B, McRae A, Dahlstrom A & Ahlman H 1993 Growth factors and carcinoid tumours. *Acta Oncologica* **32** 115–124.
- Nilsson O, Wängberg B, Kölbly L, Schultz GS & Ahlman H 1995 Expression of transforming growth factor alpha and its receptor in human neuroendocrine tumours. *International Journal of Cancer* **60** 645–651.
- Olsen BS & Holck S 1987 Neurogenous hyperplasia leading to appendiceal obliteration: an immunohistochemical study of 237 cases. *Histopathology* **11** 843–849.
- Pellegata NS, Sessa F, Renault B, Bonato M, Leone BE, Solcia E & Ranzani GN 1994 K-ras and p53 gene mutations in pancreatic cancer: ductal and nonductal tumors progress through different genetic lesions. *Cancer Research* **54** 1556–1560.
- Pizzi S, D'Adda T, Azzoni C, Rindi G, Grigolato P, Pasquali C, Corleto VD, Delle Fave G & Bordi C 2002 Malignancy-associated allelic losses on X chromosome in foregut but not in midgut endocrine tumours. *Journal of Pathology* **196** 401–407.
- Puetzal L, Lewis CE, Lorenzen J & McGee OD 1993 Growth factors: regulation of normal and neoplastic growth. *Journal of Pathology* **169** 191–201.
- Qizilbash AH 1977 Carcinoid tumors, vascular elastosis, and ischemic disease of the small intestine. *Diseases of the Colon and Rectum* **20** 554–560.
- Rigaud G, Missiaglia E, Moore PS, Zamboni G, Falconi M, Talamini G, Pesci A, Baron A, Lissandrini D, Rindi G, Grigolato P, Pederzoli P & Scarpa A 2001 High resolution alleleotype of nonfunctional pancreatic endocrine tumors: identification of two molecular subgroups with clinical implications. *Cancer Research* **61** 285–292.
- Rindi G, Buffa R, Sessa F, Tortora O & Solcia E 1986 Chromogranin A, B and C immunoreactivities of mammalian endocrine cells. Distribution, distinction from costored hormones/prohormones and relationship with the argyrophil component of secretory granules. *Histochemistry* **85** 19–28.
- Rindi G, Grant SG, Yiangou Y, Ghatei MA, Bloom SR, Bautch VL, Solcia E & Polak JM 1990 Development of neuroendocrine tumors in the gastrointestinal tract of transgenic mice. Heterogeneity of hormone expression. *American Journal of Pathology* **136** 1349–1363.
- Rindi G, Azzoni C, La Rosa S, Klersy C, Paolotti D, Rappel S, Stolte M, Capella C, Bordi C & Solcia E 1999a ECL cell tumor and poorly differentiated endocrine carcinoma of the stomach: prognostic evaluation by pathological analysis. *Gastroenterology* **116** 532–542.
- Rindi G, Capella C & Solcia E 1999b Pathobiology and classification of digestive endocrine tumors. In *Recent Advances in the Pathophysiology of Inflammatory Bowel Disease and Digestive Endocrine Tumors*, pp 177–191. Ed. MMJ Colombel. Montrouge, London, Rome: John Libbey Eurotext.
- Rindi G, Paolotti D, Fiocca R, Wiedenmann B, Henry JP & Solcia E 2000 Vesicular monoamine transporter 2 as a marker of gastric enterochromaffin-like cell tumors. *Virchows Archiv* **436** 217–223.
- Rindi G, Villanacci V, Ubiali A & Scarpa A 2001 Endocrine tumors of the digestive tract and pancreas: histogenesis, diagnosis and molecular basis. *Review of Molecular Diagnostics* **1** 323–333.
- Rode J, Dhillon AP, Doran JF, Jackson P & Thompson RJ 1985 PGP 9.5, a new marker for human neuroendocrine tumours. *Histopathology* **9** 147–158.

- Roncoroni L, Costi R, Canavese G, Violi V & Bordi C 1997 Carcinoid tumor associated with vascular malformation as a cause of massive gastric bleeding. *American Journal of Gastroenterology* **92** 2119–2121.
- Solcia E, Capella C, Fiocca R, Sessa F, LaRosa S & Rindi G 1998 Disorders of the endocrine system. In *Pathology of the Gastrointestinal Tract*, pp 295–322. Eds SC Ming & H Goldman. Philadelphia: Williams and Wilkins.
- Solcia E, Klöppel G & Sobin LH 2000 Histological typing of endocrine tumours. In *International Histological Classification of Endocrine Tumors*. New York: Springer-Verlag.
- Speel EJM, Richter J, Moch H, Egenter C, Saremaslani P, Rütimann K, Zhao JM, Barghorn A, Roth J, Heitz PU & Komminoth P 1999 Genetic differences in endocrine pancreatic tumor subtypes detected by comparative genomic hybridization. *American Journal of Pathology* **155** 1787–1794.
- Speel EJM, Scheidweiler AF, Zhao JM, Matter C, Saremaslani P, Roth J, Heitz PU & Komminoth P 2001 Genetic evidence for early divergence of small functioning and nonfunctioning endocrine pancreatic tumors: gain of 9q34 is an early event in insulinomas. *Cancer Research* **61** 5186–5192.
- Srivastava A, Alexander J, Lomakin I & Dayal Y 2001 Immunohistochemical expression of transforming growth factor α and epidermal growth factor receptor in pancreatic endocrine tumors. *Human Pathology* **32** 1184–1189.
- Theodorsson E, Ryberg B, Nilsson O, Ericson LE, Dahlström A & Ahlman H 1989 Intraocular transplants of a human gastrinoma in immunosuppressed rats: morphological, chromatographic and functional studies. *Regulatory Peptides* **24** 97–110.
- Toliat MR, Berger W, Ropers HH, Neuhaus P & Wiedenmann B 1997 Mutations in the MEN I gene in sporadic neuroendocrine tumours of gastroenteropancreatic system. *Lancet* **350** 1223.
- Tonnies H, Toliat MR, Ramel C, Pape UF, Neitzel H, Berger W & Wiedenmann B 2001 Analysis of sporadic neuroendocrine tumours of the enteropancreatic system by comparative genomic hybridisation. *Gut* **48** 536–541.
- Ubiali A, Benetti A, Papotti M, Villanacci V & Rindi G 2001 Genetic alterations in poorly differentiated endocrine colon carcinomas developing in tubulo-villous adenomas: a report of two cases. *Virchows Archiv* **439** 776–781.
- Vortmeyer AO, Lubensky IA, Merino MJ, Wang CY, Pham T, Furth EE & Zhuang Z 1997 Concordance of genetic alterations in poorly differentiated colorectal neuroendocrine carcinomas and associated adenocarcinomas. *Journal of the National Cancer Institute* **89** 1448–1453.
- Waltenberger J, Lundin L, Öberg K, Wilander E, Miyazono K, Heldin C-H & Funa K 1993 Involvement of transforming growth factor- β in the formation of fibrotic lesions in carcinoid heart disease. *American Journal of Pathology* **142** 71–78.
- Wiedenmann B & Franke WW 1985 Identification and localization of synaptophysin an integral membrane glycoprotein of Mr 38 000 characteristic of presynaptic vesicles. *Cell* **41** 1017–1028.
- Wigander A, Lundmark K, McRae A, Mölne J, Nilsson O, Haglid K, Dahlström A & Ahlman H 1991 Production of transferable neuronotrophic factor(s) by human midgut carcinoid tumour cells; studies using cultures of rat fetal cholinergic neurons. *Acta Physiologica Scandinavica* **141** 107–117.
- Wild A, Langer P, Ramaswamy A, Chaloupka B & Bartsch DK 2001 A novel insulinoma tumor suppressor gene locus on chromosome 22q with potential prognostic implications. *Journal of Clinical Endocrinology and Metabolism* **86** 5782–5787.
- Zhao JM, de Krijger RR, Meier D, Speel EJM, Saremaslani P, Muletta Feurer S, Matter C, Roth J, Heitz PU & Komminoth P 2000 Genomic alterations in well-differentiated gastrointestinal and bronchial neuroendocrine tumors (carcinoids) – marked differences indicating diversity in molecular pathogenesis. *American Journal of Pathology* **157** 1431–1438.
- Zhao JM, Moch H, Scheidweiler AF, Baer A, Schaffer AA, Speel EJM, Roth J, Heitz PU & Komminoth P 2001 Genomic imbalances in the progression of endocrine pancreatic tumors. *Genes, Chromosomes and Cancer* **32** 364–372.
- Zimring MB, Katsumata N, Sato Y, Brandi ML, Aurbach GD, Marx SJ & Friesen HG 1993 Increased basic fibroblast growth factor in plasma from multiple endocrine neoplasia type-1 – relation to pituitary tumor. *Journal of Clinical Endocrinology and Metabolism* **76** 1182–1187.